

<https://doi.org/10.37800/RM.2.2024.95-99>

UDC: 618.3-06

Successful management and delivery in a pregnant woman with brain schwannoma: A clinical case

*A.A. Yeszhanova¹, Sh.B. Kosmuratova¹, K. Zh. Khalmuratova¹, S.K. Kuanysh¹,
G.A. Sagandykova¹, S.Zh. Ibraeva²*

¹«Astana Medical University» NPJSC, Astana, the Republic of Kazakhstan;

²GKP on PVC «No. 2 City Multidisciplinary Hospital», Astana, the Republic of Kazakhstan

ABSTRACT

Relevance: Vestibular schwannoma (neurinoma of the auditory nerve, acoustic neurinoma, acoustic schwannoma) is a benign, slow-growing brain tumor that develops from the neurilemma of the upper portion of the vestibulocochlear nerve (VIII pair of cranial nerves), located 8-10 mm from the brain stem, near the inner ear canal. In 90% of cases, it is a unilateral tumor that develops due to genetic disorders in the 22nd chromosome.

The combination of pregnancy with a brain tumor is very rare and ranges from 1 case per 13-17 thousand newborns. In this case, the lives of the mother and fetus are at risk. This situation is associated with many complex obstetric, oncological, and ethical issues related to the treatment of the disease and the management of pregnancy.

The study aimed to determine the features of the management of pregnancy and childbirth in a pregnant woman with schwannoma of the brain using a clinical case as an example.

Materials and Methods: The article describes a favorable outcome of surgical treatment of cerebral schwannoma during pregnancy in weeks 25-26. The features of the tactics of pregnancy and childbirth were analyzed.

Results: At 37 weeks of pregnancy, the patient spontaneously delivered a live full-term fetus, weighing 2600 grams, height 49 cm. A positive result was obtained after neurosurgical intervention.

Conclusion: It should be noted that an interdisciplinary approach and surgical treatment of brain schwannoma allow one to prolong pregnancy to full term. Delivery in this clinical case occurred at 37 weeks of gestation due to the independent development of labor with a favorable outcome for the mother and newborn. Subsequently, the patient was observed by an outpatient neurologist.

Keywords: brain tumor, pregnancy, schwannoma.

How to cite: Yeszhanova AA, Kosmuratova ShB, Khalmuratova KZh, Kuanysh SK, Sagandykova GA, Ibraeva SZh. Successful management and delivery in a pregnant woman with brain schwannoma: A clinical case. *Reprod Med.* 2024;(2):95-99.

<https://doi.org/10.37800/RM.2.2024.95-99>

Клинический случай успешного ведения и родоразрешения беременной со шванномой головного мозга

*A.A. Eszhanova¹, Sh.B. Kosmuratova¹, K.Zh. Khalmuratova¹, S.K. Kuanysh¹,
G.A. Sagandykova¹, S.Zh. Ibraeva²*

¹НАО «Медицинский университет Астана», Астана, Республика Казахстан;

²ГКП на ПХВ «Городская многопрофильная больница №2», Астана, Республика Казахстан

АННОТАЦИЯ

Актуальность: Вестибулярная шваннома (невринома слухового нерва, акустическая невринома, акустическая шваннома) – доброкачественная, медленно растущая опухоль головного мозга, развивающаяся из неврилеммы верхней порции вестибулокохлеарного нерва (VIII пара черепно-мозговых нервов), расположенная в 8-10 мм от ствола мозга, вблизи от внутреннего слухового прохода. В 90% случаев – односторонняя опухоль, развивается вследствие генетических нарушений в 22-й хромосоме.

Сочетание беременности с опухолью головного мозга является очень редким и составляет от 1 случая на 13–17 тыс. новорожденных. В этом случае риску подвергается жизнь не только матери, но и плода. В подобной ситуации встает много сложных акушерских, онкологических и этических вопросов, касающихся не только лечения заболевания, но и ведения беременности.

Цель исследования – определить особенности тактики ведения беременности и родов у беременной со шванномой головного мозга на примере клинического случая.

Материалы и методы: Представлено описание клинического случая ведения и родоразрешения у беременной со шванномой головного мозга и результаты хирургического лечения шванномы головного мозга во время беременности пациентки.

Результаты: После хирургического лечения шванномы головного мозга на 25-26-й неделе беременности в сроке 37 недель беременности произошли самопроизвольные роды живым доношенным плодом, весом 2600 грамм, ростом 49 см. Был получен положительный результат нейрохирургического вмешательства.

Заключеніе: Междисциплинарный подход к хирургическому лечению шванномы головного мозга позволяет пролонгировать беременность до доношенного срока. Родоразрешение в данном клиническом случае произошло в сроке 37 недель беременности в связи с самостоятельным развитием родовой деятельности с благоприятным исходом для матери и новорожденного. В дальнейшем пациентка наблюдалась у врача-невропатолога в амбулаторных условиях.

Ключевые слова: опухоль головного мозга, беременность, шваннома.

Для цитирования: Есжанова А.А., Космуратова Ш.Б., Халмуратова К.Ж., Куаныш С.К., Сагандыкова Г.А., Ибраева С.Ж. Клинический случай успешного ведения и родоразрешения беременной со шванномой головного мозга // Репрод. Мед. – 2024. – №2. – С. 95-99. <https://doi.org/10.37800/RM.2.2024.95-99>

Бас миы шванномасы бар жүкті әйелді сәтті жүргізу және босанудың клиникалық жағдайы

А.А. Есжанова¹, Ш.Б. Космуратова¹, К.Ж. Халмуратова¹, С.К. Куаныш¹,
Г.А. Сагандыкова¹, С.Ж. Ибраева²

¹«Астана медицина университеті» КЕАҚ, Астана, Қазақстан Республикасы;

²ПВХ бойынша ГКП «№2 қалалық көпбейінді аурухана», Астана, Қазақстан Республикасы

АНДАТПА

Өзектілігі: Вестибулярлық шваннома (есту нервiнiң нейромасы, есту нервiнiң нейромасы, акустикалық шваннома) – (VIII бас сүйек-ми нервтерiнiң жұбы), ми бағанасынан 8-10 мм қашықтықта, iшкi құлақ арнасына жақын орналасқан вестибулокохлеарлық нервтің жоғарғы бөлiгiнiң неврилеммасынан дамiтын қатерсiз, баяу өсетiн бас ми iсiгi. 90% жағдайда бұл 22-шi хромосомадағы генетикалық бұзылуларға байланысты дамiтын бiр жақты iсiк.

Жүктiлiктiң бас ми iсiгiмен қосарлануы өте сирек кездеседi және 13-17 мың жаңа туған нәрестеге 1 жағдайды күрайды. Бұл жағдайда ананың ғана емес, ұрықтың да өмiрiне қауiп төнедi. Мұндай жағдайда ауруды емдеуге ғана емес, сонымен қатар жүктiлiктi жүргiзуге байланысты көптеген күрделi акушерлiк, онкологиялық және этикалық мәселелер туындайды.

Зерттеудiң мақсаты – клиникалық жағдайды мысал ретiнде пайдалана отырып, ми шванномасы бар жүктi әйелде жүктiлiк пен босануды басқару ерекшелiктерiн анықтау.

Материалдар мен әдiстерi: Мақалада жүктiлiктiң 25-26 аптасында бас ми шванномасын хирургиялық емдеудiң қолайлы нәтижесi келтiрiлген. Жүктiлiк және босану тактикасының ерекшелiктерi талданды.

Нәтижелерi: Жүктiлiктiң 37-шi аптасында салмағы 2600 грамм және бойы 49 см тiрi, мерзiмiнде босанумен аяқталды. Жүктiлiк барысында нейрохирургиялық араласудан кейiн нәтижесi оң болды.

Қорытынды: Бас ми шванномасын хирургиялық емдеу, пәнаралық көзқарас жүктiлiктi толық мерзiмге дейiн ұзартуға мүмкiндiк беретiнiң. Бұл клиникалық жағдайда босану жүктiлiктiң 37 аптасында босану қызметiнiң өздiгiнен басталуына байланысты ана мен жаңа туған нәресте үшiн қолайлы нәтижемен аяқталды. Әрi қарай науқас амбулаториялық негiзде невропатологтың бақылауында болды.

Түйiндi сөздер: бас ми iсiгi, жүктiлiк, шваннома.

Introduction: Vestibular schwannoma is a benign neoplasm characterized by slow growth and a non-aggressive course. Every year, 1 person per 100 thousand population falls ill with this pathology. The tumor is diagnosed at the age of 20 to 60 years and is twice more common in women [1].

Neoplasms in pregnant women are quite rare in clinical practice. The combination of pregnancy and brain tumor is an even rarer event and varies within 1 case per 13,000-17,000 births. Nevertheless, this problem is very relevant due to the difficulty of differential diagnostics of brain tumor lesions with other complications of pregnancy that have a comparatively similar clinical picture. In the early stages of pregnancy, the brain tumors can manifest in headache, nausea, and vomiting, which is mistakenly interpreted by attending physicians as a consequence of toxicosis in pregnancy, and in the second half of pregnancy, when visual impairments are possible to be apparent, as preeclampsia [2].

M. Verheecke et al. reported on 27 cases of follow-up of pregnant women, 25 of whom were diagnosed with a brain tumor in the second and third trimesters of pregnancy. Two cases of maternal mortality during pregnancy have been reported. Also, 59% of patients delivered the baby by elective cesarean section, and 52% – at 30-36 weeks of gestation [3].

Pregnancy, in combination with the brain tumor process, poses a challenge for an obstetrician-gynecologist in all aspects of the diagnostics and management of such pregnancy.

We present our clinical case of a favorable outcome for the management of a pregnant woman and a parturient woman with a brain schwannoma.

The study aimed to determine the features of the management of pregnancy and childbirth in a pregnant woman with schwannoma of the brain using a clinical case as an example.

Materials and methods: The description of a clinical case of management and delivery in a pregnant woman with

schwannoma of the brain and the results of surgical treatment of cerebral schwannoma during pregnancy have been presented.

Patient information: Pregnant Zh. was registered for pregnancy at 10-11 weeks. Complaints at the time of registration included periodic pulling pain in the lower abdomen. The life history and gynecological history were not burdened. Objective examination: no pathology. Clinical and laboratory examinations: no specific findings.

Obstetric anamnesis: Birth parity: Pregnancy – 7, natural childbirth was in the card– 3. There was a history of 2 births (1 premature, 1 urgent) and 4 spontaneous miscarriages in early pregnancy.

At 12-13 weeks, she was transferred to the second level of observation in the women's health department of the City Multidisciplinary Hospital N2, taking into account the recurrent miscarriage in anamnesis.

Clinical data: At 25-26 weeks, she called an ambulance with complaints of pulling pain when moving in the left leg, sleep disorders, and numbness of tongue, lower lip, and chin. In this regard, she was hospitalized in the obstetric unit for further observation and treatment.

In addition, from the medical history upon admission, it was found that she noted a gait impairment when walking two months ago. Over the past 3 days, she noted the tongue, lower lip, and chin numbness. The neurologist provided counseling, and the following diagnosis was established: Cerebellar ataxia, which was more pronounced on the left side. Dysarthria. Reflexory peripheral quadriplegia was more pronounced in the lower extremities. Orthostatic hypotension. The neurologist recommended electroneuromyography of the upper and lower extremities and a brain MRI with a contrasting agent. However, contrast is contraindicated in pregnancy.

Diagnostics: According to this MRI, a volumetric cystic, solid formation of the cerebellar bridge angle on the left, with dimensions of 44.3x49.4x49.8 mm, with a pronounced volumetric effect on the surrounding brain structures: Sylvian aqueduct 4 ventricle, brainstem, and both cerebellar hemispheres. The median structures of the brain at the level of the 4th ventricle are shifted to the right by 15.6 mm. Internal occlusive hydrocephaly. At the level of C2-C3 vertebrae, in the structure of intervertebral space, a nodular mass was determined, rounded shape and clearly outlined, heterogeneous structure, due to the presence of components of the fatty and soft tissue signal, which has a volumetric effect on the left vertebral artery with expansion of the vertebral artery canal at that level.

The patient was consulted by neurosurgeons at the National Center of Neurosurgery (Astana, Kazakhstan). On examination, complaints of headaches, dizziness, unsteady gait, nausea, visual impairment, and general weakness. Physical examination: VII – Facial nerve: Peripheral facial nerve paresis on the left side. Numbness of the face, tongue leftward. VIII – Vestibulocochlear nerve: hypoacusis on the left side. In Romberg's stance, she was unsteady, tending more to the left side. Coordination tests (finger-nose tests) are performed with intention. The diagnosis established: Tumor of the trigonum pontocerebellaris on the left with compression of the brain stem at the stage of clinical decompensation. Internal occlusive hydrocephaly. Cerebellar ataxia. The concomitant diagnosis: Pregnancy 25-26 weeks. Burdened obstetric history (BOH). Marginal placentation. Primary miscarriage. Papilledema of 2-3 degrees. Retinal angiopathy. The patient was hospitalized for surgical treatment.

Treatment: Surgical treatment was carried out in the hospital, which included external ventricular drainage in the projection of the anterior horn of the left lateral ventricle. Retrosigmoid approach leftward. Craniectomy of the occipital

bone leftward. Microsurgical subtotal removal of the tumor of the trigonum pontocerebellar leftward with intraoperative neuromonitoring.

Postoperative period: a brain CT after surgery revealed areas of increased density in a remote formation due to the hemorrhagic component and the presence of air. The 4-ventricle was compressed and pushed to the right up to 10 mm due to the «mass effect.» Lateral ventricles are dilated with subependymal edema. The index of anterior horns was 38%. The 3-ventricle was about 15 mm wide. The end of the shunt was determined in the 3rd ventricle.

Results: The diagnosis of «Schwannoma of the brain, WHO Grade I» was confirmed by histopathological examination. On the 14th day, she was discharged with the diagnosis: Vestibular schwannoma (grade I) leftward, with compression of the brain stem leftward in the stage of clinical decompensation. Pregnancy of 27-28 weeks. Internal occlusive hydrocephaly. Peripheral facial nerve paresis leftward, grade 2-3 on the House-Brackmann score. Cerebellar ataxia. Mild iron deficiency anemia. Chronic pyelonephritis, latent course. Primary hypothyroidism.

Labor and postpartum period: Over time, from the moment of discharge after the surgical treatment to delivery, neurological symptoms were not augmented. At 37 weeks, a live full-term fetus was born spontaneously, 2600 grams of body weight and 49 cm of body height.

After 3 months, a control MRI of the central nervous system and brain was performed; the conclusion: MRI picture of a mass cystic, solid formation in the trigonum pontocerebellare leftward, irregular shape with clear uneven contours about 30x38x35 mm in size (intensive and heterogeneous accumulation of contrast agent in the structure), exerting a volumetric effect on the surrounding structures, with displacement of the pons and brainstem to the right side. Formation of an irregular shape in the structure of the vestibulocochlear nerve at the level of the trigonum pontocerebellar on the right with clear uneven contours of dimensions of 19x10x11 mm (homogeneous and intensive accumulation of a contrast agent in the structure). There was an extensive area of glial change in the left hemisphere of the cerebellum with dimensions of about 38x32.7x22 mm. The status after surgery was at the level of the occipital region leftward, with cicatricial-fibrotic changes in subcutaneous fat. Post-trepanation defect of the frontal bone was leftward, 16 mm wide.

According to electroencephalography, three months later, the main activity was retained. Against this background, the pathological activity in low-amplitude acute waves and peaks in the parietal-central-temporal derivations on both sides are periodically registered. At the same time, rare, short, diffuse runs of low-amplitude sharp waves and peaks are observed. The pathological picture of electroencephalography.

The specialized professionals provided the counseling:

Neurosurgeon: «Given the patient's integrity, lack of data about the deterioration of the neurological status, taking into account the data of instrumental examination (MRI of the brain with contrast agent), at the time of examination, the patient does not need an emergency neurosurgical care.» The patient was recommended an electroencephalography, with further assistance from an epileptologist.

Neurologist: «At the time of examination, there was no data for acute neurological pathology. Recommended the following: follow up by a neurologist, neurosurgeon on an outpatient basis, and counseling of an epileptologist».

The timeline of the described clinical case is presented in Figure 1.

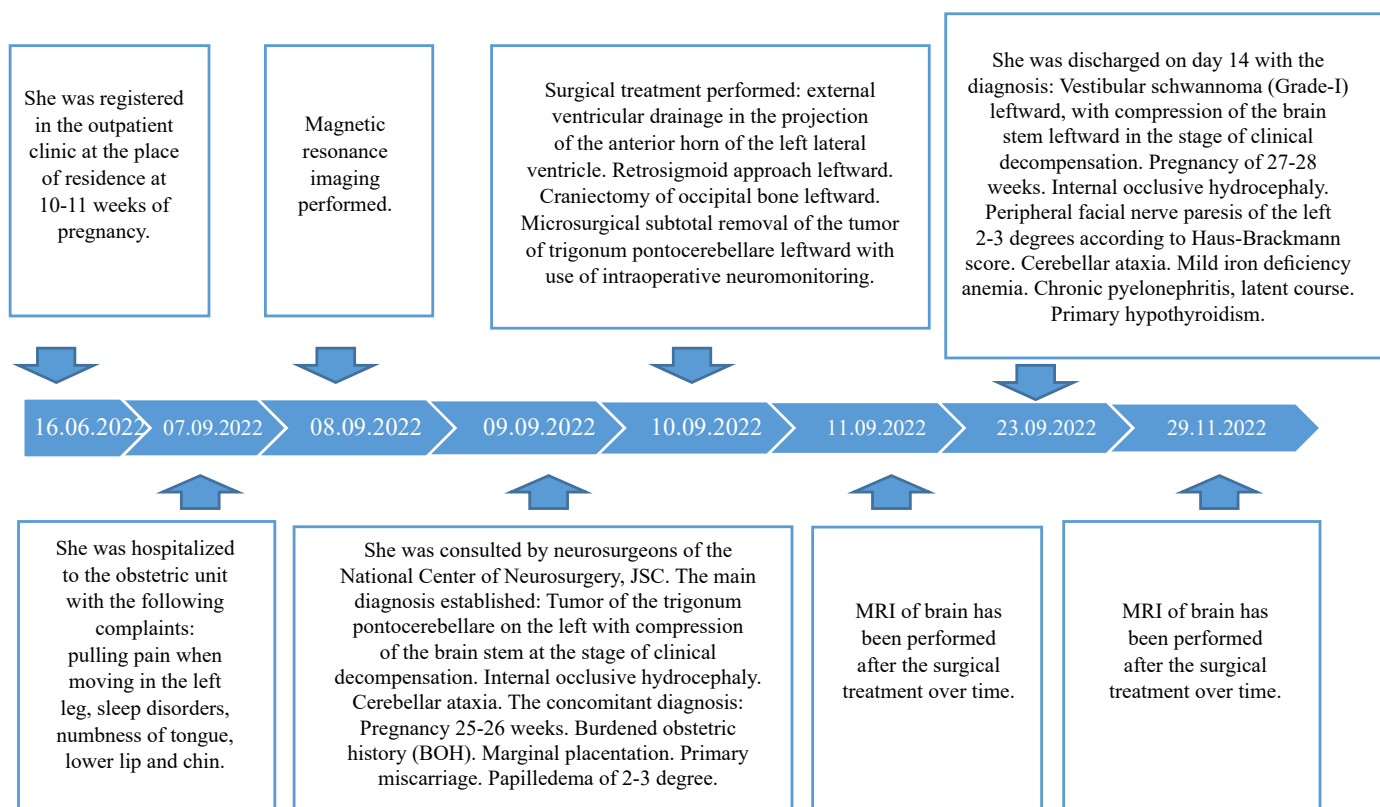


Figure 1 – Timeline of the clinical case of successful management and delivery of a pregnant woman with schwannoma of the brain

Discussion: A vestibular schwannoma in a patient is an indication for surgical treatment. The gigantic size of the tumor (> 3.5 cm) is an absolute indication for surgical treatment.

The mortality after removal of vestibular schwannomas ranges from 0 to 3%, and tumor recurrence is observed in 5-10%. The prognosis for vestibular schwannoma is favorable since the tumor is benign.

In the described case, the mild and short-term severity of the symptoms of a brain tumor did not allow for a definite diagnosis in due time. This study focused on the features of managing pregnancy and labor in a gravida with schwannoma; therefore, we did not cover the anesthesiological management during neurosurgery, the duration of surgery, or intraoperative monitoring. Also, the management of remaining internal occlusive hydrocephaly was not described since the aim was to demonstrate a successful pregnancy prolongation and delivery in the presence of a brain tumor. Neurosurgeons followed the treatment for the brain tumor.

Conclusion: The interdisciplinary approach to the surgical treatment of brain schwannoma makes it possible to prolong the pregnancy to full term. The delivery in that clinical case occurred at 37 weeks of pregnancy due to the independent development of labor with a favorable outcome for the mother and newborn. Subsequently, the patient was followed up by an outpatient neurologist.

Diagnostics and treatment of tumors during pregnancy is a difficult problem for both the patient and the doctors due to the need to choose the safest possible tactic option for the mother and fetus. It should be highlighted that benign brain tumors that require neurosurgical intervention are not a fundamental contraindication for prolongation of pregnancy. As practice shows, the surgical intervention gives a positive outcome for both the mother and the fetus if it is carried out in the postpartum period, and the outcome largely depends on the concomitant general somatic status of the patient. The success of such cases is based on the close cooperation of all multidisciplinary team members.

REFERENCES

- Шевченко Е.Н. Неврома слухового нерва (шваннома). 10.04.2024. Дата доступа: 30.04.2024. [Shevchenko E.N. Nevrinoma slухovogo nerva (shvannoma). 10.04.2024. Data dostupa: 30.04.2024. (in Russ.)]. <https://neuros.ru/lechenie/golovnoy-mozg/opuholi/nevrinoma-sluhovogo-nerva/>
- Лысяк Д.С., Закоморина Т.С. Опухоль мозжечка при беременности (клиническое наблюдение) // Amur Med. J. – 2018. – №1-2 (20-21). – P. 37-39. [Lysyak D.S., Zakomorina T.S. Opuxol' mozzhechka pri beremennosti (klinicheskoe nablyudenie) // Amurskij Med. Zhur. – 2018. – №1-2 (20-21). – S. 37-39. (in Russ.)]. <https://cyberleninka.ru/article/n/opuhol-mozzhechka-pri-beremennosti-klinicheskoe-nablyudenie>
- Verheeecke M., Halaska M.J., Lok C.A., Ottevanger P.B., Fruscio R., Dahl-Steffensen K., Kolawa W., Gziri M.M., Han S.N., Calsteren K.V., Heuvel F.V., Vleeschouwer S.D., Clement P.M., Menten J., Amant F. Primary brain tumours, meningiomas and brain metastases in pregnancy: report on 27 cases and review of literature // Eur. J. Cancer. – 2014. – Vol. 50(8). – P. 1462-1471. <https://doi.org/10.1016/j.ejca.2014.02.018>

REFERENCES

1. Шевченко Е.Н. Неврома слухового нерва (шваннома). 10.04.2024. Дата доступа: 30.04.2024. Shevchenko EN. Acoustic neuroma (shvannoma). 10.04.2024. Date of access: 30.04.2024 (Russ.). <https://neuros.ru/lechenie/golovnoy-mozg/opuholi/nevrinoma-sluhovogo-nerva/>
2. Лысяк Д.С., Закоморина Т.С. Опухоль мозжечка при беременности (клиническое наблюдение). *Амурский мед. жур.* 2018;1-2(20-21):37-39. Lysyak DS, Zakomorina TS. Cerebellar tumor during pregnancy (a clinical observation). *Amur Med J.* 2018;1-2(20-21):37-39. (Russ). <https://cyberleninka.ru/article/n/opuhol-mozzhechka-pri-beremennosti-klinicheskoe-nablyudenie>
3. Verheeecke M, Halaska MJ, Lok CA, Ottevanger PB, Fruscio R, Dahl-Steffensen K, Kolawa W, Gziri MM, Han SN, Calsteren KV, Heuvel FV, Vleeschouwer SD, Clement PM, Menten J, Amant F. Primary brain tumours, meningiomas and brain metastases in pregnancy: report on 27 cases and review of literature. *Eur J Cancer.* 2014;50(8):1462-1471. <https://doi.org/10.1016/j.ejca.2014.02.018>

Authors' data:

Yeszhanova A.A. – Assistant of the Obstetrics and Gynecology No. 2 Department, «Astana Medical University» NCJSC, Astana, the Republic of Kazakhstan, tel. 87015476982, e-mail: a.eszhanova@list.ru, ORCID ID: <https://orcid.org/0009-0002-6770-390X>

Kosmuratova Sh.B. (corresponding author) – PhD, Assistant of the Obstetrics and Gynecology No. 2 Department, «Astana Medical University» NCJSC, Astana, the Republic of Kazakhstan, tel. 87782556065, e-mail: sholpan.arenova.87@mail.ru, ORCID ID: <https://orcid.org/0000-0002-4886-2713>.

Khalmuratova K. Zh. – Master, Assistant of the Obstetrics and Gynecology No. 2 Department, Astana Medical University» NCJSC, Astana, the Republic of Kazakhstan, tel. 87016075932, e-mail: halmuratova68@mail.ru, ORCID ID: <https://orcid.org/0009-0008-4011-807743>.

Kuanysh S.K. – Assistant of the Obstetrics and Gynecology No. 2 Department, Astana Medical University» NCJSC, Astana, the Republic of Kazakhstan, tel. 87777010383, e-mail: esetova.s.k@mail.ru, ORCID ID: <https://orcid.org/0009-0005-2378-6426>.

Sagandykova G.A. – Assistant of the Obstetrics and Gynecology No. 2 Department, Astana Medical University» NCJSC, Astana, the Republic of Kazakhstan, tel. 87477797930, e-mail: sagandykova.gauxar@mail.ru, ORCID ID: <https://orcid.org/0009-0006-4500-6264>.

Ibraeva S.Zh. – Head of outpatient services Department, «No. 2 City Multidisciplinary Hospital» MSE on REM, Astana, the Republic of Kazakhstan, tel. 87015324048, e-mail: s_ibray7535@mail.ru, ORCID ID: <https://orcid.org/0009-0003-9988-4415>.

Address for correspondence: Космуратова Ш.Б., «Astana Medical University» NCJSC, Beibitshilik, 49A, 010000, Astana, the Republic of Kazakhstan.

Authors' input:

contribution to the study concept – Yeszhanova A.A., Kosmuratova Sh.B., Kuanysh S.K.

study design – Yeszhanova A.A., Kosmuratova Sh.B., Kuanysh S.K.

execution of the study – Yeszhanova A.A., Kosmuratova Sh.B., Khalmuratova K. Zh., Kuanysh S.K., Sagandykova G.A., Ibraeva S.Zh.

interpretation of the study – Yeszhanova A.A., Kosmuratova Sh.B., Kuanysh S.K., Sagandykova G.A.

preparation of the manuscript – Yeszhanova A.A., Kosmuratova Sh.B.

Funding: Authors declare no funding of the study.

Conflict of interest: Authors declare no conflict of interest.

Transparency of the study: Authors take full responsibility for the content of this manuscript.